

S. Santos¹
O. Alberti¹
T. Corbalán¹
M. T. Cortina²

Stroke-psychosis. Description of two cases

¹Neurology Department
Hospital Clínico Universitario «Lozano Blesa»
Zaragoza (Spain)

²Neurology and Psychiatry Departments
Hospital Clínico Universitario «Lozano Blesa»
Zaragoza (Spain)

Introduction. The presence of neuropsychiatry symptoms (hallucinations, delusions and agitation) as stroke-related guideline symptoms, thus forming an acute psychosis of organic cause, are extremely uncommon and often correlate with strategic infarcts (caudate nucleus, striatum and thalamus).

Clinical case. We report two cases of stroke-psychosis. Case 1: a 67-year-old man with sudden-onset delusions of persecution and complete recovery in three months. The brain magnetic resonance imaging (MRI) revealed infarctions in both head of the caudate nucleus and body of right caudate nucleus. Case 2: a 49-year-old man with sudden-onset delusions of persecution and gustative hallucinations that disappeared in three months. The brain MRI revealed small infarction in the left thalamus.

Discussion. The possible vascular origin of the psychosis in both cases (sudden onset, complete recover, demonstration of acute ischemic lesion in strategic territory) and the underlying psychopathogenic mechanism (dysfunction of prefrontal cortico-subcortical circuits) is discussed.

Key words:
Psychosis. Strategic infarct. Stroke.

Actas Esp Psiquiatr 2009;37(4):240-242

Psicosis ictal. Descripción de dos casos

Introducción. La presencia de manifestaciones neuropsiquiátricas (alucinaciones, ideación delirante, agitación psicomotriz) como síntomas guías de un evento vascular, configurando por tanto una psicosis aguda de causa orgánica es excepcional en la práctica clínica y obedece mayoritariamente a infartos estratégicos (caudado, estriado, tálamo).

Caso clínico. Se presentan dos casos de psicosis ictal. Caso 1. Varón de 67 años de edad con ideación delirante de perjuicio de instauración brusca y remisión

completa en el plazo de 3 meses. La RM cerebral demostró isquemia a nivel de ambas cabezas de núcleo caudado y cuerpo de caudado derecho. Caso 2. Varón de 49 años de edad con ideación delirante de perjuicio y alucinaciones gustativas de instauración brusca y remisión completa en 3 meses. En la RM cerebral se objetivó infarto lacunar talámico izquierdo.

Discusión. Se discute el probable origen vascular de la psicosis en ambos casos (instauración brusca, recuperación completa, demostración de lesión isquémica aguda en territorio estratégico) así como el mecanismo fisiopatogénico subyacente (disfunción de los circuitos prefrontales córtico-subcorticales).

Palabras clave:
Ictus. Infarto estratégico. Psicosis.

INTRODUCTION

Vascular origin mood alterations are relatively common in the clinical practice and include a wide spectrum, the most prevalent of them being post-stroke depression. However, the presence of neuropsychiatric manifestations (hallucinations, delusional ideation, psychomotor agitation) as guideline symptoms of a vascular event is different, these shaping an organic-caused acute psychosis. The latter has been described in association to strategic infarctions such as those located in the thalamus, head and body of the caudate and striate nucleus.

We present two clinical cases of acute psychosis as the only manifestation of strategic stroke in patients with no previous background of psychiatric disease.

CASE 1

A 67-year old male with background of smoking who was admitted to our service due to sudden-onset alteration of his usual behavior three days before his hospitalization. The clinical picture consisted in episodes of spatial disorientation and delusional ideation of persecution.

Correspondence:
Sonia Santos Lasasaosa
Servicio de Neurología
Hospital Clínico Universitario «Lozano Blesa»
San Juan Bosco, 15
50009 Zaragoza (Spain)
E-mail: ssantosl@yahoo.com

The neurological examination was consistent with normality. On the day of admission, the mental examination showed that the patient was auto- and allopsychically conscious and oriented and maintained an alert and hypervigilant attitude. His speech was spontaneous, somewhat accelerated with coherent, but digressive speech at some moment. During his interview with the on-duty Psychiatrist, he did not present any thought blockage phenomena or manifest any alterations in his thinking process. Mild dysphonic mood without apathy or anhedonia. He verbalized a delusional ideation having partially structured self-referential and persecutory content with no self-criticism. There were also probably abnormal sensory-perceptive phenomena versus delusional interpretations regarding the setting. Null awareness of disease and sense of reality decreased.

The following complementary examinations were made: blood and urine analyses, electrocardiogram (ECG), awake state electroencephalogram (EEG), simple chest X-ray, study of thyroid hormones, vitamin B12, folic acid and syphilis serology, carotid and transcranial ultrasonography, CT brain scan without contrast and Brain Magnetic Resonance Imaging (MRI) (fig. 1). There were no

significant findings except in the neuroimaging studies that showed the existence of lacunar infarctions in the head of both the caudate nucleus and body of the right caudate nucleus.

During his hospital stay, the patient was treated with quetiapine at a dose of 150 mg/day and benzodiazepines, requiring continuous follow-up by Psychiatry. The symptoms completely disappeared at the end of ten days, and he was discharged with the diagnosis of acute psychotic episode due to ischemic etiology. Ten months later, the patient is still asymptomatic and no longer continues treatment with psychodrugs.

CASE 2

A 49-year old male patient with background of bone marrow transplantation due to acute lymphoblastic leukemia and alcoholism who was admitted to our service due to sudden-onset self-referential and persecution delusion ideation. There were no visual or auditory hallucinations but he had gustative hallucinations with partial admission of them. Alteration reality judgment.

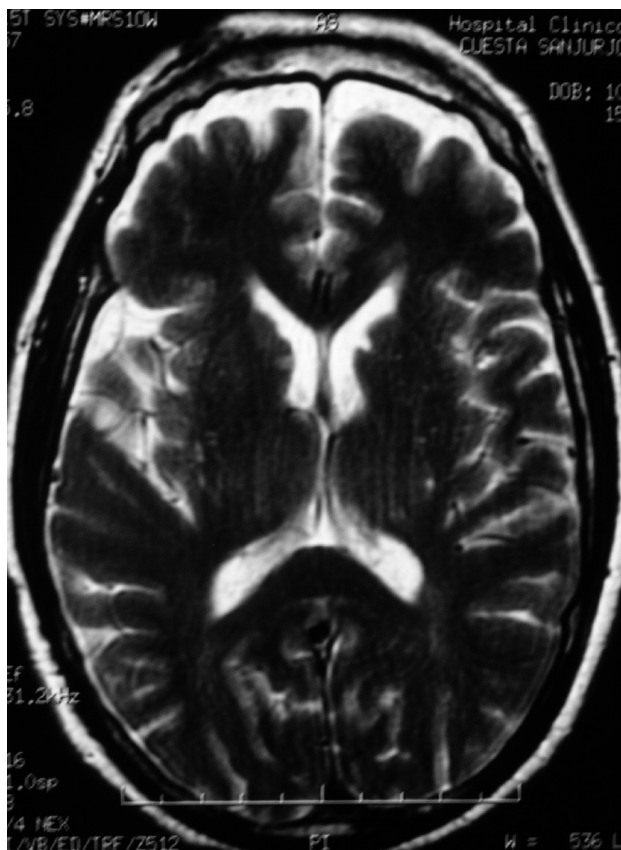


Figure 1 Case 1. Brain MRI in which lacunar infarctions are observed in both heads of the caudate and body of the right caudate

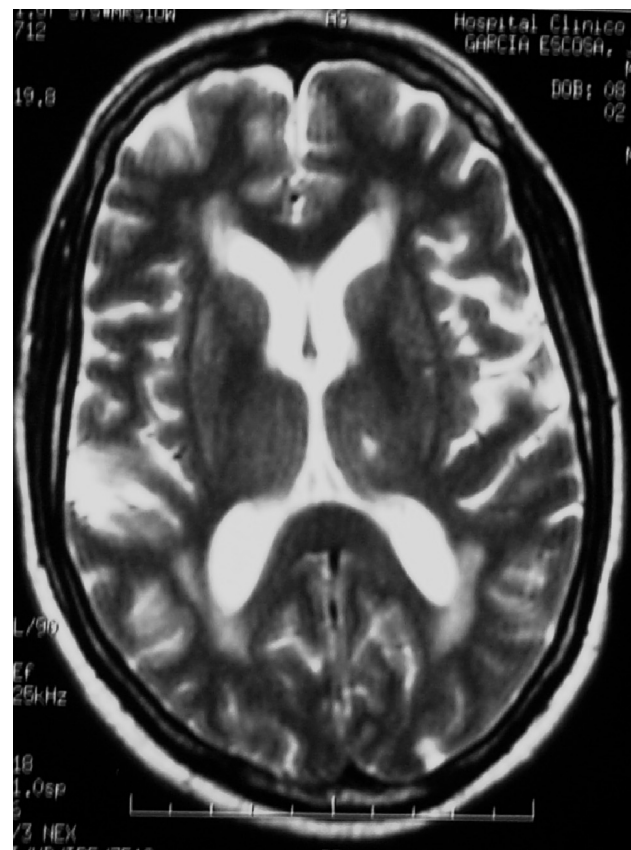


Figure 2 Case 2. Brain MRI that shows the existence of lacunar infarction in left thalamus.

The neurological examination did not show any significant alterations. A brain MRI was performed and showed left thalamic lacunar infarction. The remaining examinations performed (EEG, carotid ultrasonography) were consistent with normality. The patient was treated together with the Psychiatry service with quetiapine at a dose of 100 mg/day that was progressively withdrawn after three months of evolution due to the remission of the psychiatric symptoms.

DISCUSSION

Psychiatric manifestations in form of depression, emotional incontinence, euphoria, personality changes and cognitive deterioration are common during the evolution of stroke patients.¹ However, there are few references in the literature on patients with stroke whose initial symptoms are a psychotic type picture, this being considered as uncommon.

The frontal lobes modulate and shape character and personality. Volition, cognitive and emotional processes are congregated in them. We can distinguish four anatomic-functional regions: central motor areas, dorsolateral cortex, orbital regions and medial surface that include motor tissue of the lateral convexity and of orbital areas, including the area of the anterior cingulate. The principal cortico-cortical connections correspond to visuospatial and visuo-perceptive information processes (posterior parietal-temporal cortex). The frontal-thalamic (mainly Dorsomedial Thalamic Nucleus), frontal-limbic (formation of the hippocampus-amygdala-medial temporal lobe) and frontal-basal are distinguished within the cortico-subcortical connections. The latter are basal ganglia-thalamo-cortical circuits, anatomically and functionally separated and closed (motor, oculo-motor and prefrontal circuit). In relationship with the prefrontal circuit, Cummings² established that the subcortical structures (thalamus, striatum, and pallidus) and the prefrontal cortex shape three connection systems (dorsolateral, orbital lateral and anterior cingulate) that mediate in multiple aspects of human behavior. In this sense, Kitabayashi et al.³ present a case of schizophrenic psychosis following right putaminal lacunar infarction due to lesion of the prefrontal dorsolateral and orbital lateral circuits. Ischemia in the thalamus has also been documented in stroke psychosis.⁴ However, the development of psychotic symptoms (hallucinations and delusional ideation) is not due to the unilateral lesion of the frontal-subcortical system but rather to the interhemispheric asymmetry caused by hyperactivity or by hypoactivity of either of the two systems. Remission of psychotic symptoms after left

putaminal bleeding in a schizophrenic patient with previous ipsilateral frontal-subcortical hyperactivity has also been documented.⁵ Rabins et al.⁶ found a greater frequency of right frontoparietal lesions in patients with post-stroke psychosis and a greater degree of subcortical atrophy.

In the cases presented, the lesion was located on the level of right caudate and body (case 1) and thalamus (case 3) levels. The psychotic symptoms could be explained in the first case not so much by the dysfunction of the I dorsolateral prefrontal subcortical circuit, whose neurons come from areas 9 and 10 of Brodmann project to the dorsolateral portion of the head of the caudate nucleus and that evolve with spatial-type alteration of the work memory, but rather by the involvement of the lateral orbitofrontal circuit. This circuit (Brodmann's areas 10 and 11) projects to the ventromedial section of the caudate nucleus that extends from the head to the tail of this structure and it is precisely in the orbitofrontal cortex in which the behavior patterns are found. In the second case, the thalamus and, specifically, the dorsomedial, ventral anterior and parafascicular nuclei, the three prefrontal circuits are involved, so that in addition to behavior disorders (due to orbitofrontal dysfunction), there could be alterations in memory, learning, motivation and affect (due to anterior cingulate circuit dysfunction).

Such a sudden onset of the psychotic symptoms, the demonstration in the neuroimaging of an acute vascular event and the reversible character of the symptoms would support the diagnosis of organic psychosis, in this case secondary to ischemic infarction in strategic territory.

REFERENCES

1. Chmerinski E, Robinson R. The neuropsychiatry of stroke. *Psychosomatics* 2000;41:5-14.
2. Cummings JL. Frontal-subcortical circuits and human behavior. *Arch Neurol* 1993;50:873-80.
3. Kitabayashi Y, Narumoto J, Otakara C, Hyungin C, Fukui K, Yamada K. Schizophrenia-Like psychosis following right putaminal infarction. *J Neuropsychiatry Clin Neurosci* 2006;18:561-2.
4. McGilchrist I, Goldstein LH, Jadrjesic D, Fenwick P. Thalamo-frontal psychosis. *Br J Psychiatry* 1993;163:113-5.
5. Nagara T, Ohara H, Yano K. Disappearance of hallucinations and delusions following left putaminal hemorrhage in a case of schizophrenia. *Seishin Shinkeigaku Zasshi* 1996;98:498.
6. Rabins PV, Starkstein SE, Robinson RG. Risk factors for developing atypical (schizophreniform) psychosis following stroke. *J Neuropsychiatry Clin Neurosci* 1991;3:6-9.